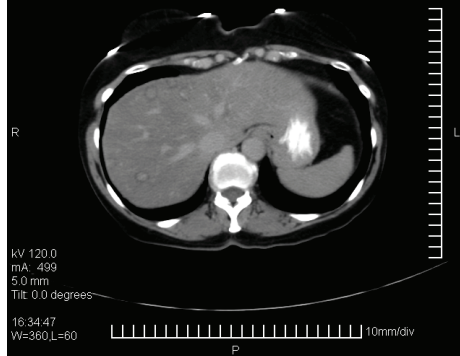
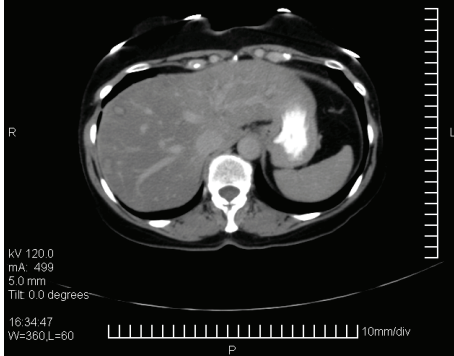


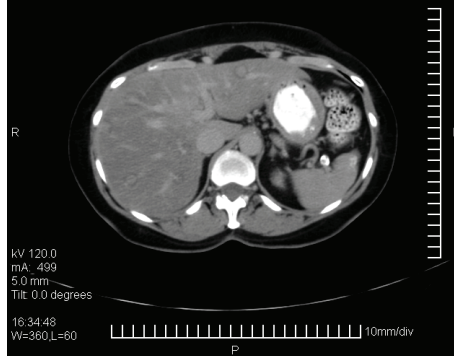
Brightness 64
Ex: 4216
Se: 3
Im: 12
DFOV: 419.0 mm



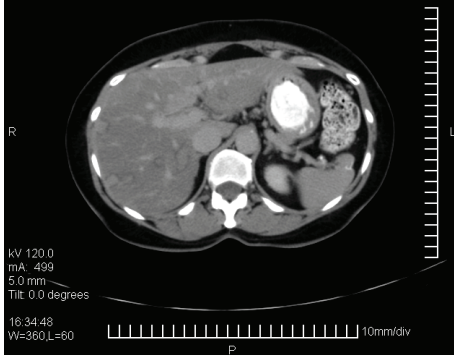
Brightness 64
Ex: 4216
Se: 3
Im: 13
DFOV: 419.0 mm



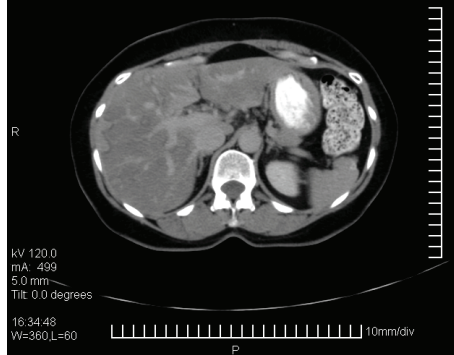
Brightness 64
Ex: 4216
Se: 3
Im: 17
DFOV: 419.0 mm



Brightness 64
Ex: 4216
Se: 3
Im: 18
DFOV: 419.0 mm



Brightness 64
Ex: 4216
Se: 3
Im: 19
DFOV: 419.0 mm



Computed tomography scan of the abdomen with oral and intravenous contrast revealed multiple target lesions worrisome for metastatic disease.